

Oral Intake of Proanthocyanidin-Rich Extract from Grape Seeds Improves Chloasma

Jun Yamakoshi^{1*}, Atsushi Sano¹, Shoichi Tokutake¹, Makoto Saito¹, Mamoru Kikuchi¹, Yoshiro Kubota², Yasuhiro Kawachi³ and Fujio Otsuka³

¹Research and Development Division, Kikkoman Corporation, Noda City, Chiba, Japan

²Kikkoman General Hospital, Chiba, Japan

³Department of Dermatology, School of Medicine, University of Tsukuba, Tsukuba, Ibaraki, Japan

Chloasma (melasma), an acquired hypermelanosis, is often recalcitrant to various treatments and an amenable, as well as safe, pigment-reducing modality is needed. We investigated that the reducing effect of proanthocyanidin, a powerful antioxidant, on chloasma in a one-year open design study. Proanthocyanidin-rich grape seed extract (GSE) was orally administered to 12 Japanese woman candidates with chloasma for 6 months between August 2001 and January 2002 and to 11 of these 12 for 5 months between March and July 2002. Clinical observation, L* value (lightening) and melanin index, and size (length and width) measurements of chloasma were performed throughout the study period. The first 6 months of GSE intake improved or slightly improved chloasma in 10 of the 12 women (83%, $p < 0.01$) and following 5 months of intake improved or slightly improved chloasma in 6 of the 11 candidates (54%, $p < 0.01$). L* values also increased after GSE intake (57.8 ± 2.5 at the start vs 59.3 ± 2.3 at 6 months and 58.7 ± 2.5 at the end of study). Melanin-index significantly decreased after 6 months of the intake (0.025 ± 0.005 at the start vs 0.019 ± 0.004 at 6 months) ($p < 0.01$), and also decreased at the end of study (0.021 ± 0.005) ($p < 0.05$). GSE is effective in reducing the hyperpigmentation of women with chloasma. The beneficial effects of GSE was maximally achieved after 6 months and these was no further improvement after this period. The latter GSE intake for 5 months may prevent chloasma from becoming worse prior to the summer season. GSE is safe and useful for improving chloasma. Copyright © 2004 John Wiley & Sons, Ltd.

Keywords: proanthocyanidin; procyanidin; grape seed extract; antioxidant; chloasma; melasma.

INTRODUCTION

Abnormal facial pigmentation like chloasma (melasma) is often of great cosmetic importance to women. However, the treatment has always been challenging and discouraging (Pérez-Bernal *et al.*, 2000). Chloasma is a common acquired symmetrical hypermelanosis characterized by irregular light to dark brown macules and patches on sun-exposed areas of the skin (Kang *et al.*, 2002). It has been documented in people of all races but is more common in those exposed highly to ultraviolet (UV) radiation (Pérez-Bernal *et al.*, 2000). Although the etiology is unknown, several etiogenic factors have been implicated, including genetic factors, UV exposure, pregnancy, hormonal therapies, cosmetics, phototoxic drugs and antiseizure medications (Kang *et al.*, 2002). The sun exposure is the most important factor, and is present in all patients (Pérez-Bernal *et al.*, 2000), who improve or worsen with sun exposure (Pérez-Bernal *et al.*, 2000).

UV radiation can act on melanocytes directly (Friedmann and Gilchrist, 1987; Eller *et al.*, 1996) or indirectly through the release of keratinocyte-derived factors and are known to increase melanization and

even induce proliferation (Kupper *et al.*, 1989; Bos and Kapsenberg, 1993; Kondo *et al.*, 1993). UV radiation is also well known to induce reactive oxygen species (ROS) in the skin and melanin biosynthesis in melanocytes (Gilchrist *et al.*, 1996; Ablett *et al.*, 1998). Then ROS are likely to play an important role in the pathogenesis of chloasma. Antioxidants, ROS scavengers and inhibitors of ROS production, have recently attracted much attention in the treatment of chloasma expecting the prevention of UV-induced melanogenesis and/or the reduction hyperpigmentation. Vitamin C and vitamin E have been reported to improve chloasma especially by their combined administration (Hayakawa *et al.*, 1981). Pycnogenol® (French maritime pine bark extract) is another antioxidant and contains proanthocyanidins, monomeric phenolic compounds and phenolic acids. It has been recently reported to improve chloasma in a relatively shorter period of administration (Ni *et al.*, 2002). However, patients with chloasma were evaluated by method of semi-quantitative analysis, and the season of test period was unknown. We have formulated proanthocyanidin-rich grape seed extracts (GSE) as a healthy food supplement and have demonstrated that GSE is a strong antioxidant and reduces melanin biosynthesis as well as UV-induced hyperpigmentation in guinea pigs (Yamakoshi *et al.*, 2003).

Thus we investigated quantitatively if GSE improve facial hyperpigmentation of Japanese women with chloasma. To evaluate the long-term efficacy of GSE intake, a one-year study was performed.

* Correspondence to: Dr J. Yamakoshi, Research and Development Division, Kikkoman Corporation, 399 Noda, Noda City, Chiba, 278-0037, Japan.
E-mail: jyamakoshi@mail.kikkoman.co.jp

MATERIALS AND METHODS

Grape seed extract. The Grape Seed Extract (GSE; Gravinol™, Kikkoman Co., Chiba, Japan) containing 81.0% proanthocyanidins was used for this study. The extracts were prepared from grape seeds (*Vitis vinifera* L.); the method of preparation was described elsewhere (Koga *et al.*, 1999; Yamaguchi *et al.*, 1999). Proanthocyanidins, which are oligomers and polymers of polyhydroxy flavan-3-ol units, such as (+)-catechin and (-)-epicatechin (Fig. 1), are present in large amounts in polyphenols of red wine and grape seed (Waterhouse and Walzem, 1998; Carando and Teissedre, 1999). Only the procyanidin-type of proanthocyanidins has been detected in grape seeds (Santos-Buelga *et al.*, 1995). The GSE is now commercially available as a nutritional supplement in the United States, Australia, Japan, Korea, as well as in other countries. GSE is also being used in the United States as self-affirmed generally recognized as safe (GRAS) and Japan as an additive for various food applications.

Study design on facial hyperpigmentation of women with chloasma. This investigation was performed in accordance with the Helsinki Declaration, as updated in Tokyo in 1975. An open design study was conducted for one year between the first day of August 2001 and the end of July 2002. Twelve nonpregnant Japanese women aged 34 to 58 years (average of age, 45.4 ± 6.1 years) with chloasma were candidates and enrolled at the start of the study period. Age of onset of chloasma averaged 34 years (range 30–50), and the average time which chloasma was present prior to study entry was 12 years (range 3–21). Of the 12 women who were enrolled, 11 completed the entire one-year study period. One woman (age: 58 years) dropped out of the study after 6 months of GSE intake. The reason for dropping out was a change of residence. These ages of 11 of the 12 candidates were 34–51 years (average of age, 44.8 ± 4.6 years). Sixty-seven mg of GSE (54 mg of proantho-

cyanidin) was orally administered three times a day for 6 months between the first day of August 2001 and the end of January 2002, and for 5 months between the first day of March 2002 and the end of July 2002. They did not receive any treatments of chloasma and hormonal therapy. They did not receive any medication and did not drink red wine during the test period, and direct solar exposure was avoided as much as possible by using some sunshades (hat and umbrella).

Reflectance spectrophotometric evaluation. A reflectance spectrophotometer (Minolta CM-2600d, Tokyo, Japan) was used as a measure of chloasma (hyperpigmented lesion) and normal-appearing skin color. These measures of skin color were based on the $L^*a^*b^*$ color system as defined by the Commission Internationale de l'Éclairage (Robertson, 1976). In this system, L^* is a measure of skin value or darkness/lightness. Although the L^* value may range from 0 (black) to 100 (white), the range obtained in human skin is much narrower (Andreassi *et al.*, 1990). The skin measuring area using the reflectance spectrophotometer was 3 mm in diameter (surface 7.1 mm^2). Measurements were taken monthly by the same investigator, and particular care was taken to ensure that the reflectance spectrophotometer was held perpendicular to the assessment area, and that minimal pressure was applied, in order to avoid skin blanching. The diameters of hyperpigmented lesions were in the range 3.5–5.5 mm and could easily be positioned within the aperture of the measurement head (3 mm in diameter). The investigator always confirmed that the assessment area was only designated hyperpigmented lesion or only normal-appearing skin site, and the area did not contain the lesion and normal-appearing skin site together by a finder of the spectrophotometer. The instrument was always calibrated using a white calibration plate before the measurement. The designated sites of 32 and 30 lesions of the 12 and 11 women with chloasma (2–3 lesions per a woman) and 12 and 11 areas of normal-appearing skin on the left cheeks of these women were measured by the instrument in the study respectively. Three sequential measurements were taken from each site, and mean values aggregated for purposes of statistical analysis. The melanin-index was calculated using the data obtained with the reflectance spectrophotometer according to the method of Feather *et al.* (1988). Several theoretical models for the optical properties were presented, and it was demonstrated that measurements of skin reflectance at several selected wavelengths could be used as indices of cutaneous melanin and haemoglobin (Dawson *et al.*, 1980; Feather *et al.*, 1988; Takiwaki *et al.*, 1994). The reflectances of the skin at 640 and 670 nm wavelengths obtained from SpectraMagic software (Minolta, Tokyo, Japan) connected to the reflectance spectrophotometer. The melanin-index was mainly influenced by the melanin content (Feather *et al.*, 1988; Takiwaki *et al.*, 1994), and the index was calculated (Feather *et al.*, 1988) as follows;

$$\text{Melanin index} = \log_{10}(1/\text{reflectance of 640 nm}) - \log_{10}(1/\text{reflectance of 670 nm})$$

Clinical evaluation. Clinical evaluation of overall response was made at baseline before GSE intake (July 2001), and monthly to the end of study (July 2002). The

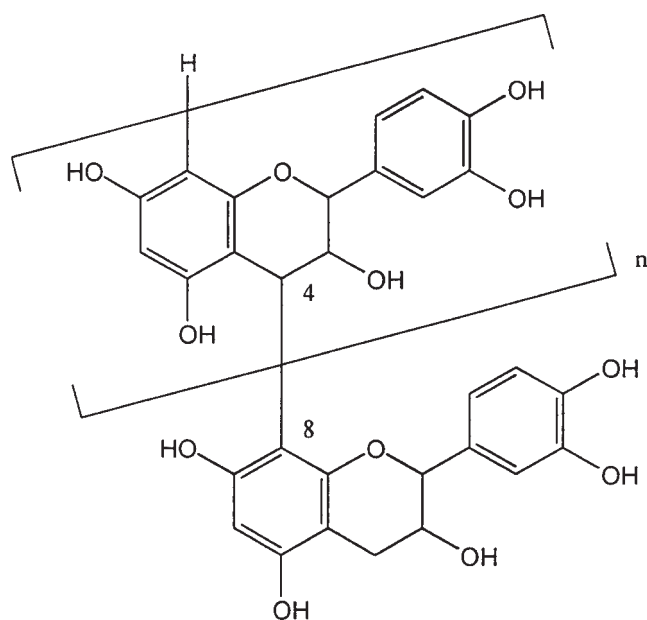


Figure 1. A representative structure of procyanidins from grape seeds. The 'n' means the number of catechin units. $n \geq 1$.

effectiveness of the lightening of chloasma (hyperpigmented lesion) was judged by the reflectance spectrophotometer according to the method of Kameyama *et al.* (1996), with only minor modifications. If the L^* value increased more than 3.0 as compared with the L^* value at before GSE intake, it was defined as improved, an increase of 1.0 to 3.0 was defined as slightly improved; an increase or a decrease less than 1.0 was defined as unchanged; a decrease of 1.0 to 2.0 was defined as slightly aggravated; and a decrease of more than 2.0 was defined as aggravated. The size (length and width) of chloasma was measured monthly by electronic calipers.

Before GSE intake (July 2001), the history of melasma, relationship to pregnancy, sun exposure and cosmetic use was taken. These candidates were asked monthly whether or not they were directly or indirectly exposed to the sun. Local cutaneous side effects such as inflammation and erythema were also recorded monthly.

Photography. Full frontal and side views of the face were photographed monthly before and during intake using standardized positioning and lighting criteria. The photographs for documentation of the lesional areas and normal-appearing skin sites were also taken using the same criteria.

Statistical Analysis. Fisher's test was used to evaluate of the degree of clinical improvement in the women with chloasma. A one-way ANOVA with Tukey's significant difference test was also used to evaluate differences among the groups.

RESULTS

Fig. 2A and B show the face of a woman with chloasma before and 6 months after GSE intake. GSE intake remarkably improved the chloasma (Fig. 2B). GSE intake improved chloasma as slightly improved in five (42%, $p < 0.05$) of 12 candidates after 3 months. Ten (83%, $p < 0.01$) of the 12 were rated as improved or slightly improved after 6 months of GSE intake, and six (54%, $p < 0.01$) of the 11 were also rated at the end of study (12 months), compared with baseline of chloasma before the intake (Table 1). The L^* value (lightening) increased in chloasma after 4 to 6 months of GSE intake (57.84 ± 2.48 at the start vs 58.28 ± 1.96 at month 4, 58.55 ± 2.32 at month 5, and 59.25 ± 2.31 at month 6), and also increased in chloasma at the end of study (58.70 ± 2.52 at 12 months), but the value was almost the same in normal-appearing skin of these candidates between the start and the end of study (62.49 ± 2.96 at the start vs 62.60 ± 1.46 at 12 months) (Fig. 3). The melanin-index decreased in cloasma after 3 to 12 months of study (0.025 ± 0.005 at the start vs 0.024 ± 0.005 at month 3, 0.019 ± 0.004 at month 6, and 0.021 ± 0.005 at month 12), especially at months 6–12 (at the start vs months 6–9; $p < 0.01$, at the start vs month 12; $p < 0.05$); however, the value did not change in normal-appearing facial skin of these candidates (0.015 ± 0.006 at the start vs 0.015 ± 0.004 at month 6 and 0.014 ± 0.003 at month 12) (Fig. 4). The size of chloasma decreased after GSE intake (length and width; $4.42 \pm$

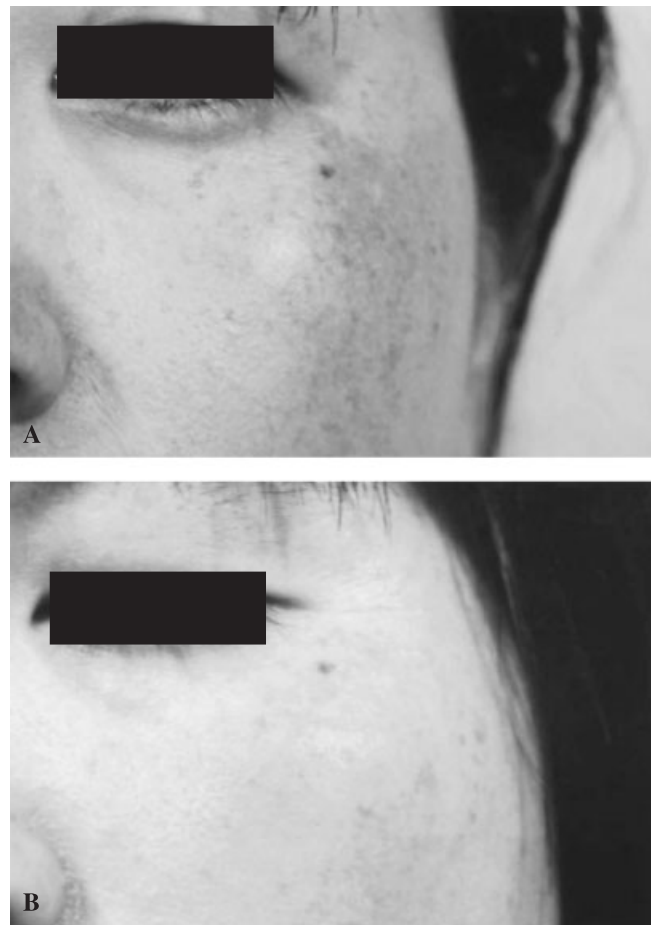


Figure 2. Clinical photographs of a 34-year-old woman with chloasma. Hyperpigmented lesions on her cheek (A) improved after 6 months of GSE intake (B).

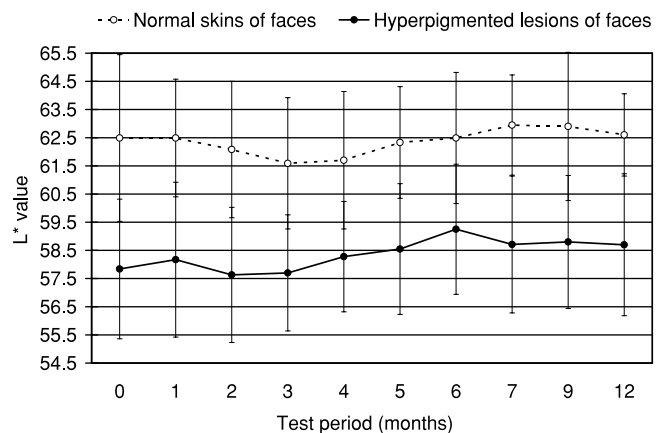


Figure 3. GSE intake and L^* value. L^* value indicates the lightness of the skin color: 11–12 normal-appearing skin of the face and 30–32 chloasmas were evaluated in the study. Values were expressed as a mean \pm SD.

0.82 mm and 4.44 ± 0.93 mm at the start vs 4.10 ± 0.71 mm and 4.07 ± 0.77 mm at month 6, and 4.26 ± 0.66 mm and 4.17 ± 0.78 mm at month 12) (Fig. 5).

The chloasma of one woman was slightly aggravated at month 2 and 3 of the study, and chloasma of another woman aggravated at month 12 of the study (Table 1). These women reported exacerbation of chloasma following sports on a day of high sun intensity.

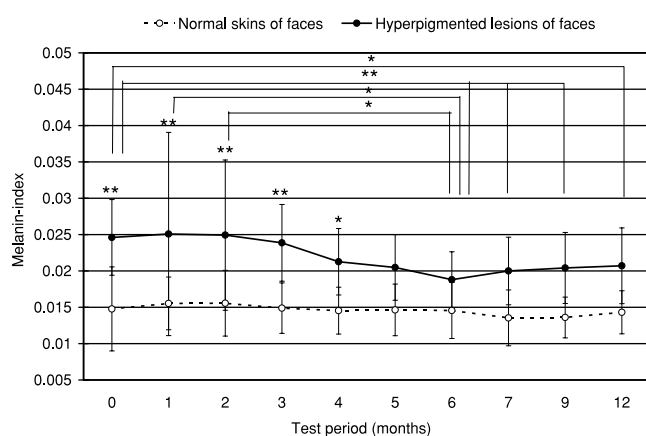


Figure 4. GSE intake and melanin-index. The melanin-index, which is mainly influenced by the melanin content, was calculated according to the method of Feather *et al.* (1988). The number of normal-appearing skin and chloasmas evaluated is the same as that in Fig. 3. *: $p < 0.05$, **: $p < 0.01$. Values were expressed as mean \pm SD.

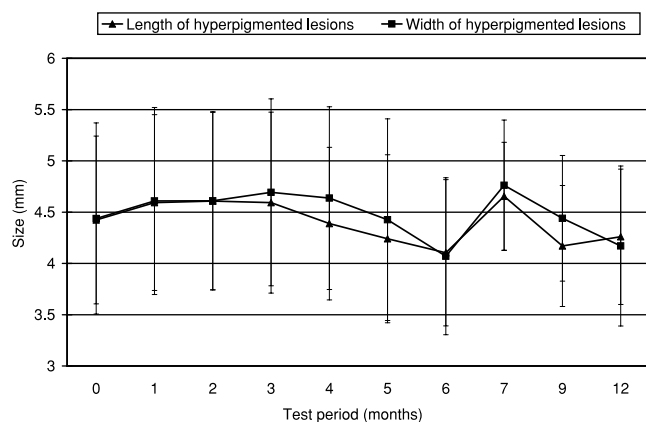


Figure 5. GSE intake and size (length and width) of chloasma. The size of chloasmas evaluated is the same as that in Fig. 3.

Chloasmas of several women became worse during the 1 month, between month 6 and month 7 of the study, when all the candidates did not take GSE (Table 1, Fig. 3–5). These candidates reported that they were not directly or indirectly exposed to the sun during the 1 month.

No adverse side effects related GSE intake were observed on the skin of all the candidates.

DISCUSSION

We investigated if oral intake of GSE, a proanthocyanidin-rich extract from grape seeds and a powerful antioxidant, reduced facial hyperpigmentation of Japanese women with chloasma in a one-year study. GSE improved chloasma clinically as well as in terms of the L^* value, the melanin-index, and size measurements at the end of the study (12 months), as compared with these at the start. No adverse side effects related to GSE intake were observed on the skin of all the candidates throughout the study period. The reducing effect on hyperpigmentation was readily apparent. Chloasma of several women became worse during the month 1, between month 6 and month 7 of the study, when the candidates did not take GSE. Following 5 months of intake of GSE, chloasma hyperpigmentation improved slightly or reached the condition obtained by the previous 6 month-GSE intake (Table 1, Fig. 3 and 4). The beneficial effects of GSE was maximally achieved after 6 months and there was no further improvement after this period. The latter GSE intake may prevent chloasma from becoming worse prior to the summer season. This level of chloasma may be the maximum condition obtained by GSE intake in this study design. Taken together, these results indicate that oral intake of GSE successfully and safely improve facial chloasma hyperpigmentation.

Chloasmas of a few women were aggravated during the study period. These women reported exacerbation of chloasma following sports on a day of high sun intensity. The exacerbation of chloasma improved after about 1 month of the sun exposure (Table 1). It was strongly suggested that the exacerbation of chloasmas was due to the sun exposure. A sunscreen which protects against both ultraviolet A and B should be used by individuals with chloasma during the study period.

UV radiation, an important causative factor in chloasma induces ROS formation in the skin and then melanin pigment biosynthesis (Libow *et al.*, 1988; Gilchrest *et al.*, 1996; Horikoshi *et al.*, 2000). GSE has a

Table 1. Improvement Rating^a of Chloasma

	Improved	Slightly improved	Unchanged	Slightly aggravated	Aggravated	Total effective (Total number of Improved + Slightly improved)
One months	0	1 (8%)	11 (92%)	0	0	1 (8%)
Two months	0	2 (16%)	9 (75%)	1 (8%)	0	2 (16%)
Three months	0	5 (42%)	6 (50%)	1 (8%)	0	5* (42%)
Four months	1 (8%)	7 (58%)	4 (34%)	0	0	8** (66%)
Five months	2 (16%)	6 (50%)	4 (34%)	0	0	8** (66%)
Six months	3 (25%)	7 (58%)	2 (17%)	0	0	10** (83%)
Seven months	1 (9%)	6 (55%)	1 (9%)	2 (18%)	1 (9%)	7** (64%)
Nine months	2 (18%)	2 (18%)	5 (46%)	2 (18%)	0	4* (36%)
Twelve months	2 (18%)	4 (36%)	4 (36%)	0	1 (9%)	6** (54%)

^a The clinical improvement was evaluated as compared with baseline of chloasma before the intake of proanthocyanidin-rich grape seed extract (GSE).

*: $p < 0.05$, **: $p < 0.01$.

strong free radical scavenging activity (Ricardo *et al.*, 1991; Yamaguchi *et al.*, 1999). It is stronger than that of vitamin C, vitamin E, and the combination of both *in vitro* experimental systems (Bagchi *et al.*, 1998). When ¹⁴C-labelled GSE was administered orally to mice, radioactivity was observed in various organs, but a preferential binding to the skin, aorta and gastrointestinal mucosa has been demonstrated (Laparra *et al.*, 1978). We have recently demonstrated that GSE strongly suppresses melanin pigment formation and the feeding of GSE has an apparent lightening effect on UV-induced hyperpigmentation in guinea pig skin (Yamakoshi *et al.*, 2003). The latter effect was stronger with GSE than with vitamin C (Yamakoshi *et al.*, 2003). Our study demonstrating that oral intake of GSE reduces chloasma hyperpigmentation is consistent with our recent experimental results in guinea pigs. Consider-

ing the dose of GSE used in this study, GSE is likely to inhibit melanogenesis or even melanocyte proliferation only in the chloasma area, i.e. to work only in highly melanogenic and/or even proliferative melanocytes in chloasma.

In conclusion, the oral administration of proanthocyanidin-rich extract from grape seeds (GSE) effectively reduced the hyperpigmentation of women with chloasma. GSE was safe and useful for improving chloasma.

Acknowledgements

We thank Dr S. Ishii, Research and Development Division, Kikkoman Corporation, for helpful discussion and suggestions, and also thank Mrs Y. Shimaoka, and Mrs S. Yamamoto, Research and Development Division, Kikkoman Corporation, for their technical assistance.

REFERENCES

- Ablett E, Pedley J, Dannoy PA, *et al.* 1998. UVB-specific regulation of gene expression in human melanocytic cells: cell cycle effects and implication in the generation of melanoma. *Mutat Res* **422**: 31–41.
- Andreassi L, Casini L, Simoni S, *et al.* 1990. Measurement of cutaneous color and assessment of skin type. *Photodermatol Photoimmunol Photomed* **7**: 20–24.
- Bagchi D, Garg A, Krohn RL, *et al.* 1998. Protective effects of grape seed proanthocyanidins and selected antioxidants against TPA-induced hepatic and brain lipid peroxidation and DNA fragmentation, and peritoneal macrophage activation in mice. *Gen Pharmac* **30**: 771–776.
- Bos JD, Kapsenberg ML. 1993. The skin immune system: progress in cutaneous biology. *Immunol Today* **14**: 75–80.
- Carando S, Teissedre P-L. 1999. Catechin and procyanidin levels in French wines: contribution to dietary intake. In *Plant Polyphenols 2: Chemistry, Biology, Pharmacology, Ecology*. Gross GG, Hemingway RW, Yoshida T (eds). Kluwer Academic/Plenum publishers; New York; 725–737.
- Dawson JB, Barker DJ, Ellis DJ, *et al.* 1980. A theoretical and experimental study of light absorption and scattering by *in vivo* skin. *Phys Med Biol* **25**: 695–709.
- Eller MS, Ostrom K, Gilchrist BA. 1996. DNA damage enhances melanogenesis. *Pro Natl Acad Sci USA* **93**: 1087–1092.
- Feather JW, Ellis DJ, Leslie G. 1988. A portable reflectometer for the rapid quantification of cutaneous haemoglobin and melanin. *Phys Med Biol* **33**: 711–722.
- Friedmann PS, Gilchrist BA. 1987. Ultraviolet radiation directly induces pigment production by cultured human melanocytes. *J Cell Physiol* **133**: 88–94.
- Gilchrist B, Park HY, Eller MS, Yaar M. 1996. Mechanisms of ultraviolet light-induced pigmentation. *Photochem Photobiol* **63**: 1–10.
- Hayakawa R, Ueda H, Nozaki T, *et al.* 1981. Effects of combination treatment with vitamins E and C on chloasma and pigmented contact dermatitis. A double blind controlled clinical trial. *Acta Vitaminol Enzymol* **3**: 31–38.
- Horikoshi T, Nakahara M, Kaminaga H, *et al.* 2000. Involvement of nitric oxide in UVB-induced pigmentation in guinea pig skin. *Pigment Cell Res* **13**: 358–363.
- Kang WH, Yoon KH, Lee E-S, *et al.* 2002. Im S. Melasma: histopathological characteristics in 56 Korean patients. *Br J Dermatol* **146**: 228–237.
- Kameyama K, Sakai C, Kondoh S, *et al.* 1996. Inhibitory effect of magnesium L-ascorbyl-2-phosphate (VC-PMG) on melanogenesis *in vitro* and *in vivo*. *J AM Acad Dermatol* **34**: 29–33.
- Koga T, Moro K, Nakamori K, *et al.* 1999. Increase of antioxidative potential of rat plasma by oral administration of proanthocyanidin-rich extract from grape seeds. *J Agric Food Chem* **47**: 1892–1897.
- Kondo ST, Kono T, Sauder DN, McKenzie RC. 1993. IL-8 gene expression and production in human keratinocytes and their modulation by UVB. *J Invest Dermatol* **101**: 690–694.
- Kupper TS, Min K, Sehgal P, *et al.* 1989. Production of IL-6 by keratinocytes. Implications for epidermal inflammation and immunity. *Ann NY Acad Sci* **557**: 454–464.
- Laparra J, Michaud J, Lesca MF, *et al.* 1978. Etude pharmacocinetique des oligomeres procyanidoliques totaux du raisin. *Acta Therapeutica* **4**: 233–246.
- Libow LF, Scheide S, Deleo VA. 1988. Ultraviolet radiation acts as an independent mitogen for normal human melanocytes in culture. *Pigment Cell Res* **1**: 397–401.
- Ni Z, Mu Y, Gulati O. 2002. Treatment of melasma with Pycnogenol®. *Phytother Res* **16**: 567–571.
- Pérez-Bernal A, Muñoz-Pérez MA, Camacho F. 2000. Management of facial hyperpigmentation. *Am J Clin Dermatol* **1**: 261–268.
- Ricardo da Silva JM, Darman N, Fernandez Y, Mitjavila S. 1991. Oxygen free radical scavenger capacity in aqueous models of different procyanidins from grape seeds. *J Agric Food Chem* **39**: 1549–1552.
- Robertson AR. 1976. The CIE 1976 color difference formulas. *COLOR Res Appl* **2**: 7–11.
- Santos-Buelga C, Francia-Aricha EM, Escribano-Bailón MT. 1995. Comparative flavan-3-ol composition of seeds from different grape varieties. *Food Chem* **53**: 197–201.
- Takiwaki H, Overgaard L, Serup J. 1994. Comparison of narrow-band reflectance spectrophotometric and tristimulus colorimetric measurements of skin color. Twenty-three anatomical sites evaluated by the Dermaspectrometer and the Chroma Meter CR-200. *Skin Pharmacol* **7**: 217–225.
- Waterhouse AL, Walzem RL. 1998. Nutrition of grape phenolics. In *Flavonoids in Health and Disease*, Rice-Evans CA, Packer L (eds). Marcel Dekkar: New York; 359–385.
- Yamaguchi F, Yoshimura Y, Nakazawa H, Ariga T. 1999. Free radical scavenging activity of grape seed extract and antioxidants by electron spin resonance spectrometry in an H₂O₂/NaOH/DMSO system. *J Agric Food Chem* **47**: 2544–2548.
- Yamakoshi J, Otsuka F, Sano A, *et al.* 2003. Lightening effect on ultraviolet-induced pigmentation of guinea pig skin by oral administration of proanthocyanidin-rich extract from grape seeds. *Pigment Cell Res* **16**: 629–638.